

MYOBACTERIOSIS IN TURTLES: CUTANEOUS AND HEPATOSPLENIC INVOLVEMENT IN A *Phrynops hilari* [□]

ANDERS G. J. RHODIN and MIRIAM R. ANVER, Department of Anatomy and The Unit for Laboratory Animal Medicine, University of Michigan Medical School, Ann Arbor, Michigan 48109, USA

Abstract: Mycobacteriosis in a *Phrynops hilari* (side-necked turtle) was characterized by multiple caseating granulomas in the liver and spleen; pulmonary involvement did not occur. Granulomatous inflammation and organisms also were present in the skin, suggesting a cutaneous route of entry with hematogenous spread to visceral organs. Review of the four cases of chelonian mycobacteriosis in the literature indicated that pulmonary tubercles and plastral ulcerations are typical manifestations. The *Mycobacterium* species usually involved is *M. chelonci*.

INTRODUCTION

Mycobacterial infections in fish, amphibians and snakes occur commonly, but reported cases of mycobacteriosis in turtles are rare. Four have been described in the literature,^{1,4,19} with none in the last 27 years. These four include two cases of pulmonary tubercles in *Chelone corticata* (*Caretta caretta*),⁴ one case of plastral ulcerations plus pulmonary tubercle in *Trionyx triunguis*¹ and one case of plastral ulcerations in *Trionyx gangeticus*.¹⁹

Several authors state that mycobacteriosis in turtles is characterized by pulmonary tubercles,^{3,13,14,15,20,21} whereas snakes, lizards and crocodiles are more subject to cutaneous and hepatosplenic involvement.^{15,20,21} Several other reviews of reptilian and chelonian mycobacteriosis have appeared over the years,^{2,5,9,10,11,17,19} but new statements on chelonian involvement have been scarce. One investigator⁷ states that the only definite report of death due to mycobacteriosis in turtles occurred in two *Chelydra serpentina*, but a reference is not cited.

This report describes the finding of atypical chelonian mycobacteriosis in a side-necked turtle, *Phrynops hilari* (Testudines: Chelidae).

CASE HISTORY

The turtle was acquired from Argentina in October, 1974, and was housed with several other species of turtles in a large aquarium containing a filter and a basking area. Diet consisted of raw smelt, with supplements of raw beef, ocean perch and fresh earthworms. The turtle died in April, 1975, after a two month course of progressive deterioration, during which it ate almost nothing but continued to gain weight. Five months prior to death it developed a chronic nodular ulceration with granulation tissue on the mandible, and one month prior to death similar nodules developed in the webbing of the forefeet. At death there was marked axillary and inguinal edema. None of the other turtles in the aquarium developed similar findings.

NECROPSY RESULTS

Body weight at time of death was 790 g. Extensive subcutaneous edema and massive ascites was present. The liver was markedly enlarged and weighed 69 g. Multiple discrete white nodules (2-10 mm diameter) were present on the capsular surface of the liver as well as in

[□] This investigation was supported in part by Resource Grant No. RR-00200, Animal Resources Branch, Division of Research Resources, National Institutes of Health.

the parenchyma (Fig. 1). On section, a whitish capsule with a brown core was evident. A single similar nodule was present in the parenchyma of the spleen. None were noted in the lungs, kidneys, gastrointestinal tract, pancreas, heart, thyroid or genitourinary tract. Unfortunately, the chronic nodular ulcerative lesion on the mandible was destroyed during skeletal preparation of the skull, but a similar lesion from the webbing of one of the forefeet showed a granulating nodule with ragged edges. A speculative diagnosis of metastatic carcinoma to the liver and spleen was made on the basis of the multiple nodularity, and specimens for bacteriology were not collected at the time of necropsy.

MICROSCOPIC RESULTS

Lesions in the liver and spleen consisted of multiple granulomas. The granulomas had cores of caseous necrotic material which was sometimes laminated; epithelioid cells surrounded the necrotic debris and each granuloma had a fibrous capsule (Fig. 2). Giant cells were not found. Focal granulomatous peritonitis was present overlying some of the subcapsular nodules.

Epithelium was intact in the nodule from the webbing of the forefoot, but the dermis contained sheets of epithelioid cells interspersed with foci of fibrin and necrosis (Fig. 3).

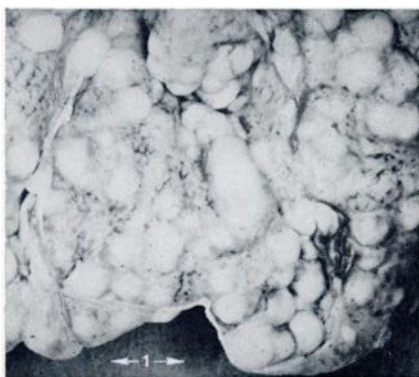

FIGURE 1. Multiple white nodules in the liver (scale in cm).

Masses of acid fast, gram positive, short bacterial rods were present in the centers of hepatic and splenic granulomas (Fig. 2); numerous organisms also were found in the dermal lesion. The bacteria had staining characteristics and morphology typical of *Mycobacterium spp.*

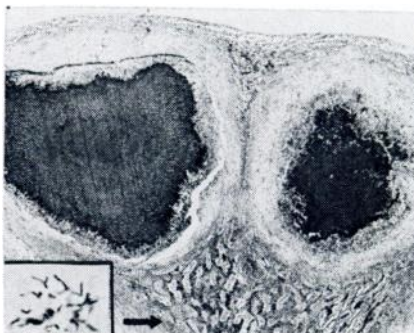


FIGURE 2. Photomicrograph of subcapsular hepatic granulomas with laminated, caseous necrotic centers; remnants of liver parenchyma at arrow. H & E stain; x17. Insert: numerous acid fast bacilli from center of hepatic granulomas. Fite-Faraco stain; x1000.

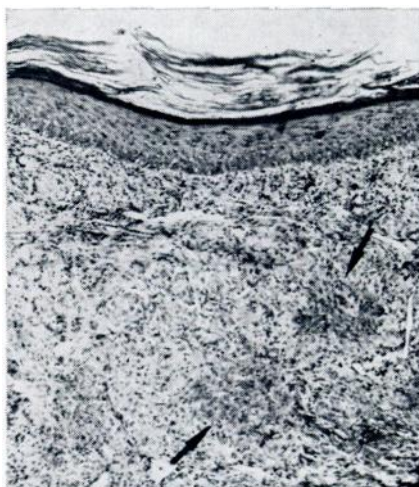


FIGURE 3. Photomicrograph of webbing of forefoot with granulomatous dermatitis. Necrosis and fibrin (arrows) surrounded by epithelioid cells. H & E stain; x64.

DISCUSSION

Likely the portal of entry for the *Mycobacterium sp.* was cutaneous, with hematogenous spread to liver and spleen. The ascites and subcutaneous edema probably were secondary to portal hypertension and hypoalbuminemia, both resulting from the massive hepatic damage.

An analysis of the five cases of chelonian mycobacteriosis now known indicates that pulmonary involvement is not as characteristic as once thought. Rather, it would appear that turtles do not differ markedly from other reptiles in their response to infection by mycobacteria.

The *Mycobacterium sp.* usually associated with infection in turtles is *M. chelonae* (synonyms: *M. friedmannii*, *M. abscessus*, *M. runyoni* and *M. borsta-*

lense) which is an atypical *Mycobacterium* classified as a Runyon group IV or rapid grower. It is a saprophytic organism and considered only mildly pathogenic for man, occasionally causing subcutaneous abscesses at sites of injuries.^{8,12} Recently, however, *M. chelonae* has been implicated as a rare cause of thyroiditis¹⁰ and an occasional cause of sternotomy infections following open-heart surgery.⁹

How commonly mycobacterial infection occurs in turtles is yet to be established, and whether such infection is usually related to a preceding debilitated state is not known. In addition, the epidemiologic role of chelonian and reptilian mycobacteriosis in the pathogenesis of human disease remains an unanswered question.

LITERATURE CITED

1. BESSE, P. 1949. Quelques affections a bacilles acido-resistants chez les poecilothermes vivant en aquarium. Bull. Acad. Vet. France 22: 426.
2. COWAN, D. F. 1968. Diseases of captive reptiles. J. Am. vet. med. Ass. 153: 848-859.
3. DOYLE, R. E. and A. F. MORELAND. 1968. Diseases of turtles. Lab Anim. Dig. 4: 3-6.
4. FRIEDMANN, F. F. 1903. Spontane Lungentuberkulose bei Schildkroten und die Stellung des Tuberkelbazillus im System. Zeitschr. Tuberk. 4: 439-457.
5. GRIFFITH, A. S. 1930. Tuberculosis in cold-blooded animals. In: *A System of Bacteriology in Relation to Medicine*. Medical Research Council (Great Britain). Vol. 5: 326-332.
6. HINES, M. P., R. WAGGONER and T. M. VERNON, Jr. 1976. Atypical mycobacteria wound infections—North Carolina, Colorado. Morb. Mort. Week. Rep. 25: 238, 243.
7. HUNT, T. J. 1957. Notes on diseases and mortality in Testudines. Herpetologica 13: 259-272.
8. INMAN, P. M. 1969. Outbreak of injection abscesses due to *Mycobacterium abscessus*. Arch. Dermatol. 100: 141-147.
9. KAPLAN, H. M. 1957. The care and diseases of laboratory turtles. Lab. An. Care 7: 259-272.
10. MARCUS, L. C. 1968. Diseases of snakes and turtles. In: *Current Veterinary Therapy III*. Kirk, R. W., ed. Philadelphia: W. B. Saunders. pp. 435-442.
11. ————. 1971. Infectious diseases of reptiles. J. Am. vet. med. Ass. 159: 1626-1631.
12. MOORE, M. and J. B. FRERICHS. 1953. An unusual acid-fast infection of the knee with subcutaneous abscess-like lesions of the gluteal region: report of a case with the study of the organism *Mycobacterium abscessus*. J. Invest. Derm. 20: 133-168.

13. MURPHY, J. B. 1973. A review of diseases and treatment of captive chelonians—bacterial and viral infections. Part two of a series. *HISS News—Journal* 1: 77-81.
14. ———. 1975. A brief outline of suggested treatments for diseases of captive reptiles. *Soc. Stud. Amph. Rept. Misc. Publ. Herp. Circ.* 4: 1-13.
15. REICHENBACH-KLINKE, H. and B. ELKAN. 1965. *The Principal Diseases of Lower Vertebrates*. Academic Press, New York, N.Y. pp. 385-543.
16. RODGERS, B. M., W. WOLFE and D. E. DETMER. 1975. Atypical mycobacterial infection of the thyroid gland. *J. Pediatr. Surg.* 10: 827-829.
17. SATO, S. 1970. Tuberkuloseartige Erkrankungen bei Kaltblutern. In: Meissner, G. and A. Schmiedel, eds. *Mykobakterien und mykobakterielle Krankheiten*. Teil VII. Jena; Gustav Fischer. pp. 380-393.
18. SCOTT, H. H. 1930. In: *Tuberculosis in Man and Lower Animals*. Spec. Rept. Serv. Medical Research Council (Great Britain), 149: 1-270.
19. VOGEL, H. 1958. Mycobacteria from cold-blooded animals. *Am. Rev. Tuberc. Pulm. Dis.* 77: 823-838.
20. WALLACH, J. D. 1969. Medical care of reptiles. *J. Am. vet. med. Ass.* 155: 1017-1034.
21. ———. 1968. Diseases of reptiles and their clinical management. In: *Current Veterinary Therapy IV*. Kirk, R. W., ed. Philadelphia, Pa. W. B. Saunders. pp. 435-442.

Received for publication 30 September 1976
